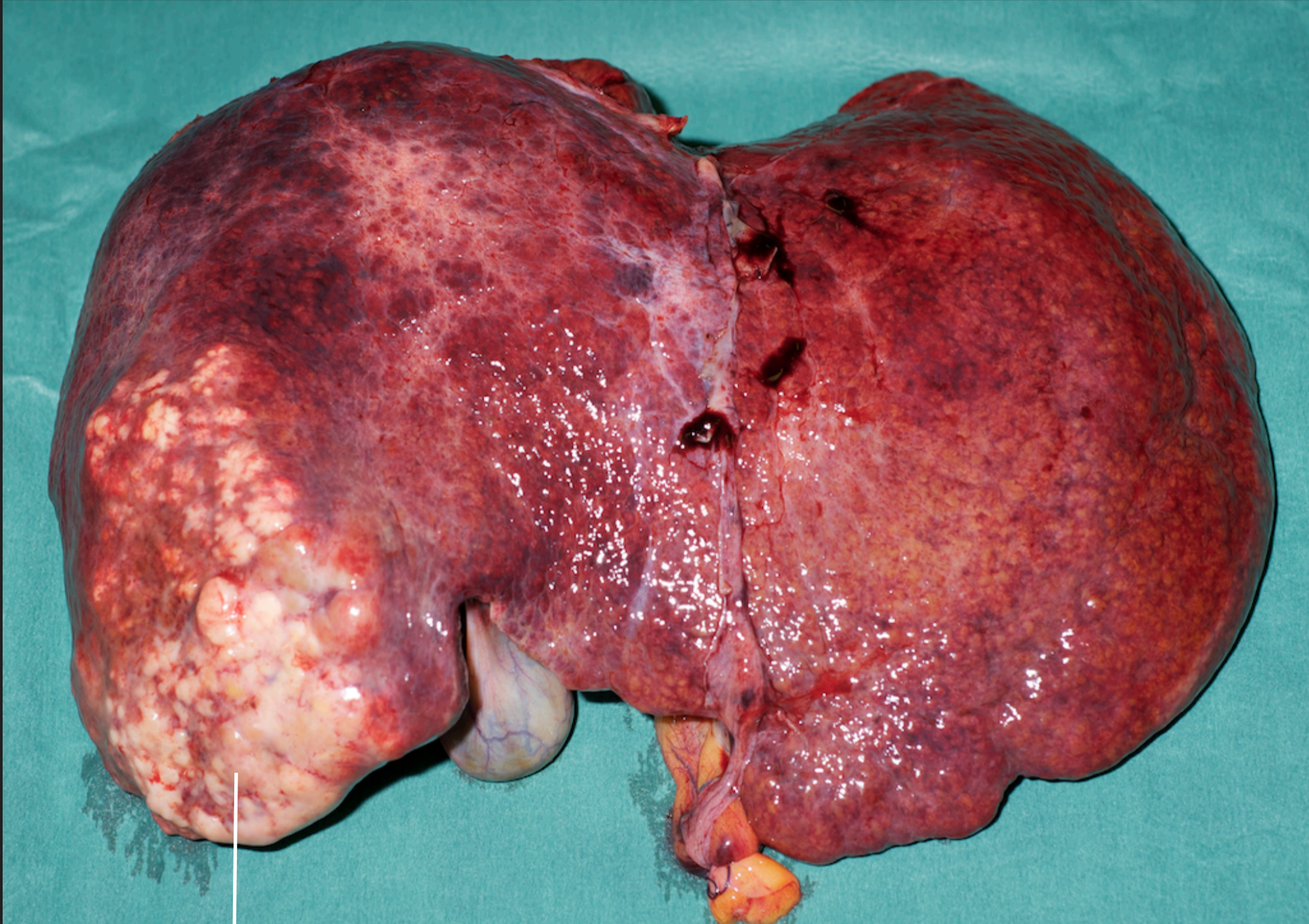


Hepatocellular carcinoma in a cirrhotic liver.

The patient had cirrhosis secondary to hepatitis C and the tumour was thought to be under 5cm pre-transplant; at surgery it was apparent it was larger than expected.



Hepatocellular carcinoma